

MINIMAL STANDARD TERMINOLOGY FOR GASTROINTESTINAL ENDOSCOPY

*WEO (formerly known as OMED) committee for
standardization and terminology*

Lars Aabakken, Norway (chairman 2008)

Bjorn Rembacken, UK

Olivier LeMoine, Belgium

Konstantin Kuznetsov, Russia

Jean-Francois Rey, France

Thomas Rösch, Germany

Glen Eisen, US

Peter Cotton, US

Masayuki Fujino, Japan

MST 3.0



Copyright 2008 World Endoscopy Organization (formerly known as OMED). All rights reserved.

Permission is hereby granted, without written agreement and without license or royalty fees, to use, copy, or distribute the Minimal Standard Terminology (MST) for any purpose, so long as this copyright notice appears on any copies of the MST and that the following conditions are met.

- The notice of WEO (formerly known as OMED) copyright (above) should be displayed on every copy of the MST, on all manuals and other materials used in connection with the MST, including electronic media (disks, CD ROMs, etc.) and should be apparent in text files loaded on these disks or onto the Internet.
- The content of the defined core MST fields must not be changed. Users may add list items and sub-classification of items as needed, as long as the diversion from the core MST structure is documented and traceable.

WEO (formerly known as OMED) and the members of the Committee for Standardization and Terminology do not accept liability for any omissions or errors in the MST and all EXPRESS AND IMPLIED WARRANTIES, INCLUDING THOSE RELATING TO MERCHANTABILITY OR FITNESS FOR A PARTICULAR PURPOSE, ARE DISCLAIMED.

1	Introduction	3
1.1	Development	3
1.2	MST 3.0.....	3
1.3	Modifications to the MST	4
2	Anatomical structures	5
2.1	Luminal anatomy	5
2.2	Hepatobiliary anatomy.....	6
2.3	Procedure/organ diagram.....	7
2.4	EUS anatomy	8
3	Endoscopic findings and their attributes.....	11
3.1	Luminal findings.....	11
3.2	Luminal findings per organ	14
3.3	ERCP findings	16
3.4	ERCP findings per organ.....	17
3.5	EUS findings.....	18
3.6	EUS lesion-specific attributes lists.....	21
3.7	EUS findings per organ	22
4	Reasons for endoscopy.....	24
4.1	Upper endoscopy	24
4.2	Colonoscopy.....	25
4.3	Enteroscopy.....	25
4.4	ERCP	26
4.5	EUS.....	27
5	Endoscopic diagnosis	28
5.1	Upper endoscopy	28
5.2	Colonoscopy.....	29
5.3	Enteroscopy.....	30
5.4	ERCP	31
5.5	EUS.....	31
6	Procedures	34
6.1	Luminal procedures	34
6.2	ERCP procedures.....	37
6.3	EUS procedures	38
7	Adverse events.....	40
7.1	Intraprocedure events.....	40
7.2	Postprocedure events.....	40
7.3	Actions and outcomes	41
8	Appendices.....	42
8.1	Classifications.....	42

1 Introduction

1.1 Development

Since computers became more readily available and relatively inexpensive, there has been increasing interest in their use for recording the findings at endoscopy. The advantages are that it is possible to search any database created, perform statistical analysis, and avoid the need for hand-written or typed reports. Around the world, a considerable number of endoscopy record systems have been developed but there has been no standardization of the terminology used. As a result, a golden opportunity has been lost for sharing and comparing data collected from different centers.

Following a meeting on "Computers in Endoscopy" organized by Pr. M. Classen in Munich in 1991, it became apparent that this important problem needed resolution. ESGE organized a committee under the chairmanship of Pr. M. Crespi and included a number of experts from Belgium, France, Germany, Hungary, Italy, Spain and the United Kingdom. Dr. Maratka from Czech Republic was invited to join the Committee because of his hallmark on endoscopic terminology for the World Endoscopy Organization (formerly known as OMED). At an early stage, it was felt important that the other World Zones be represented and representatives from the USA and Japan were added to the Committee. Additionally, the three major endoscope manufacturers (Fujinon, Olympus and Pentax) and the publisher Normed-Verlag were invited to join the committee as it was imperative that industry should be involved in this work as they were developing their own systems and compatibility between these was regarded as vital if the opportunities for sharing data were to be optimized. It was also important that these companies be involved in discussing other aspects, such as image capture, storage and transfer.

Between 1992 and 1993, a series of meetings of this Committee were held, concluding with a joint meeting of the ESGE group and the Computer Committee of the American Society for Gastrointestinal Endoscopy (ASGE). At this time, the work was reviewed and modified and the Committee was constituted as the Working Party for this report for the World Congresses of Gastroenterology and Digestive Endoscopy.

The major aim of the project was to devise a "minimal" list of terms that could be included within any computer system used to record the results of a gastrointestinal endoscopic examination. The lists should not be exhaustive, and the work should not result in complete software. Rather, the MST should form the basis for various software vendors to facilitate common structure and language. In addition, the MST should provide assistance in the standardization of endoscopic image storage and transfer between individual systems and in the structure of reports.

The list of terms proposed relied heavily upon the original and detailed work performed by the WEO (formerly known as OMED) committee under the chairmanship and guidance of Pr. Z. Maratka. His book provides the framework, as well as the definitions for most of the MST terminology. This will provide a reference for users unfamiliar with the words employed.

MST 1.0 formed the basis for prospective testing of the Terminology in Europe and the United States. This testing was funded by the European Commission through the Gaster Project and the American Digestive Health Foundation. This work resulted in a number of modifications implemented in the **MST 2.0** in 2000. Since then, this version of the MST has been implemented in a number of software solutions, mostly with various modifications.

1.2 MST 3.0

The MST copyright and responsibility was transferred to the WEO (formerly known as OMED) society for further development. The committee of terminology and standardization has been in charge of this task, which has resulted in the present **MST 3.0** version. While the original ideas of Prof. Maratka, ESGE, ASGE and the Gaster project have been retained, some modifications have still been put in place in this revision.

- EUS and enteroscopy (including capsule endoscopy) have been included
- The lists of findings have been reorganized, with one generic list for each main category (luminal, ERCP, EUS). This is coupled with a table to indicate which findings are relevant for which organ.
- The ERCP terminology has been revised to allow more precise description of maneuvers, as well as findings
- The lists for indications and diagnoses have been extended and somewhat revised.
- New sections on therapy and adverse events have been included.
- Updated classifications have been included as attributes wherever relevant.

1.3 Modifying the MST

The discipline of endoscopy is constantly evolving, and it is performed quite differently between centers, countries and cultures. Thus, although there are some items of the endoscopic language and structure that remain, there is a continuous need for flexibility and customization. This has implications for the MST document. While offering standards for core items, it should offer, even encourage, enough flexibility for users to accept the inherent structure and limitation of any standard. Thus, making modifications within the recommendations in the copyright statement is probably vital to an acceptable role of the MST.

Also, by presenting the MST 3.0 in an interactive context on the WEO (formerly known as OMED) website, we hope to collect feedback from users that will help improving the document even more.

The MST offers a selection of terms and attributes for appropriate description of findings, procedures and complications. It does not offer a complete reference for the endoscopic report. However, when developing software for endoscopic reporting the MST should be considered as structuring guidance and for initial selection of list terms available.

The relevant local modifications would be

- Adding items to a list
- Removing irrelevant items from a list
- Adding sub-classifications within the main MST items
- Adding attributes with corresponding values

2 Anatomical structures

All findings should be have a location attribute. The lists below show the appropriate locations within each organ. In addition, certain modifying terms, e.g. *cm from incisors* may be applied.

2.1 Luminal anatomy

Organ	Site	Modifier
Esophagus	Esophagus	xx cm from incisors/nares
	Cricopharynx	
	Upper third	
	Middle third	
	Lower third	
	z-line	
	Cardia	
	Whole esophagus	
	Anastomosis	
Stomach	Stomach	Greater curve
	Cardia	Lesser curve
	Fundus	Anterior wall
	Body	Posterior wall
	Incisura/angulus	xx cm from incisors
	Antrum	xx cm from the GE junction
	Prepyloric region	xx cm from pylorus
	Pylorus	
	Whole stomach	
	Anastomosis	
	Hiatal hernia	
	Diaphragm orifice	
Duodenum	Duodenum	Proximal
	Duodenal bulb	Distal
	D2 - 2nd part of duodenum	Whole
	D3 - 3rd part of duodenum	Whole examined
	D4 - 4th part of duodenum	
	Upper duodenal knee/ superior duodenal angulus	
	Ampullary region	
	Major papilla	
	Minor papilla	
	Lower duodenal knee/ inferior duodenal angulus	
	Anastomosis	

Jejunum	Jejunum	xx cm from lig of Treitz
	Ligament of Treitz	xx min from pylorus
	Afferent loop	Proximal
	Efferent loop	Distal
	Jejunal crest	Whole
	Roux-y-limb	Whole examined
	anastomosis	Type (specify)
	stoma	
Ileum¹	Ileum	xx cm from ileocecal valve
	Stoma	xx cm from stoma
		xx min from cecum
		Proximal
		Distal
		whole
		whole examined
Colon	Colon	xx cm from anus
	anus	xx cm from stoma
	rectum	proximal
	Sigmoid colon	mid
	Descending colon	distal
	Splenic flexure	whole
	Transverse colon	whole examined
	Hepatic flexure	
	Ascending colon	
	Cecum	
	Ileocecal valve	
	Anastomosis	type (specify)
	Pouch	
	Stoma	

2.2 Hepatobiliary anatomy

Organ	Site	Modifier
Biliary tree	Major papilla	
	Whole biliary tree	
	Common bile duct ²	whole
		upper
		mid
		lower

¹ Jejunum-ileal transition: Where the typical jejunal mucosal pattern disappears and allows to guess where the endoscope reaches the upper ileal segment.

² The common bile duct denotes the entire extrahepatic bile duct, excluding the cystic duct.

		terminal
		xx cm from papilla
		above
		below
	Cystic duct	
	Cystic duct takeoff	
	Gallbladder	
	Bifurcation/Hilum	
	Anastomosis	
	Left hepatic duct	central ³
	Right hepatic duct	peripheral
	Left intrahepatic branches	v
	Right intrahepatic branches	v
	Segment xx branch	v
Pancreatic duct	Major papilla	xx cm from the papilla
	Minor papilla	whole
	Whole pancreatic duct	upstream
	Head	downstream
	Neck	central
	Body	peripheral
	Tail	
	Uncinate process	
	Ventral duct	
	Dorsal duct	
	Duct of Santorini	
	Duct of Wirsungi	
	Side branches	

2.3 Procedure/organ diagram

This diagram shows what organs would be relevant for individual endoscopic procedures.

	EGD	Enteroscopy	VCE	Colonoscopy	ERCP
Esophagus	x	x	x		x
Stomach	x	x	x		x
Duodenum	x	x	x		x
Jejunum	x	x	x		x
Ileum		x	x	x	
Colon		x	x	x	
Biliary tree					x
Pancreatic duct					x

³ Central and peripheral relate to all intrahepatic structures

2.4 EUS anatomy

Organ	Site	Modifier
Esophagus	esophageal wall	right
	upper esophagus	left
	mid esophagus	xx cm from incisors
	lower esophagus	
	cardia	
	mediastinum	
	periesophageal	
	paraesophageal	
	subcarina	
	pleura	
	lung	
	trachea	
	main bronchus	
	left atrium	
	pericardium	
	aortopulmonary window	
	diaphragm	
	crus	
	spine	
	carotid artery	
	Subclavian artery	
	aortic arch	
	thoracic aorta	
	pulmonary artery	
	superior vena cava	
	inferior vena cava	
	azygos vein	
lymph node station xx	station no	
Stomach	Stomach	Greater curve
	Cardia	Lesser curve
	Fundus	Anterior wall
	Body	Posterior wall
	Incisura	xx cm from incisors
	Antrum	xx cm from the GE junction
	Prepyloric region	xx cm from pylorus
	Pylorus	xx mm from GI wall
	Whole stomach	
	Anastomosis	
	Hiatal hernia	
	Gastric wall	
	celiac axis	
	perigastric	
	left kidney	
	spleen	
	splenic hilum	

	left adrenal	
	portal vein	
	splenic vein	
	portal confluence	
	splenic artery	
	left renal artery	
	left renal vein	
	hepatic artery	
	superior mes artery	
	superior mes vein	
	left gastric artery	
Duodenum	Duodenum	Proximal
	Duodenal bulb	Distal
	D2 - 2nd part of duodenum	
	D3 - 3rd part of duodenum	
	D4 - 4th part of duodenum	
	Upper duodenal knee/superior duodenal angulus	
	Ampullary region	
	Major papilla	
	Minor papilla	
	Anastomosis	
	duodenal wall	
	periduodenal	
	right kidney	
	right adrenal	
	Inferior vena cava	
	Aorta (abdominal)	
Biliary tract	Major papilla	
	Whole biliary tree	
	Common bile duct	whole
		upper
		mid
		lower
		terminal
		xx cm from papilla
		Above
		Below
	Cystic duct	
	Cystic duct takeoff	
	Gallbladder	
	Bifurcation	
	generalized	
	peribiliary	

Pancreas	Major papilla	xx cm from the papilla
	Minor papilla	whole
	Whole pancreatic duct	upstream
	head	downstream
	neck	central
	body	peripheral
	tail	
	Uncinate process	
	ventral duct	
	dorsal duct	
	Duct of Santorini	
	Duct of Wirsungi	
	Side branches	
	generalized	
	peripancreatic	
Colorectum	colorectal wall	proximal
	anal canal	mid
	lower rectum	distal
	mid rectum	xx cm from anus
	upper rectum	xx cm from stoma
	rectosigmoid junction	
	sigmoid	
	descending colon	
	transverse colon	
	ascending colon	
	cecum	
	terminal ileum	
	perianal	
	perirectal	
	pericolonic	
	prostate gland	
	seminal vesicles	
	urinary bladder	
	uterus	
	vagina	
	sacrum	
	puborectalis muscle	
	internal sphincter	
	external sphincter	
	anastomosis	

3 Endoscopic findings and their attributes

Most of these findings are general and relate to all or most of the organs and structures available to GI endoscopy. The findings share the same attributes regardless of location. Thus, they are described together, with an additional table to indicate which findings are relevant for which organs.

For each finding, the recommended attributes that should be described are listed. In addition, the *location* attribute (chapter 3) applies to all findings.

3.1 Luminal findings

Heading	Term	Attribute	Attr values	
Lumen	Normal			
	Dilation			
	Stenosis		Appearance	Benign
				Malignant
			Length	xx cm
			Traversable	Yes
				After dilation
				No
	Compression		size	small
				large
	Diverticulum		Number	Single
				Multiple
			Size	Small
				Large
			Neck	Narrow
				Wide
		Content	None	
			Food	
			Blood	
			Clot	
	Previous surgery	Type	Specify	
	Deformity	Type	Specify	
	Ring/web	Lumen	xx mm	
	Hiatal hernia	Upper border	cm from incisors	
		Lower border	cm from incisors	
	Z-line	position	cm from incisors	
Contents	Foreign body	Type	Specify..	
	Blood	Type	Fresh	
			Clot	
			Hematin	
	Food			
	Bezoar	Type	Specify..	
	Fluid	Type	Specify..	
	Parasites	Type	Specify..	
	Stent	Type	Specify..	

	Gastrostomy	Type	Specify..
	Faeces		
	Exudate		
Mucosa	Erythematous	Distribution	Localised
	Edematous		Patchy
	Granular		Generalised
	Nodular		v
	Friable		v
	Hemorrhagic		v
	Petechial		v
	Atrophic		v
	Sclerosis/scarring		
	Barretts esophagus	Extent	CM-classification
	Esophagitis	Grade	LA-classification
		Bleeding	Yes
			Bleeding stigmata
			No
	Candidosis/candidiasis	Distribution	Localised
	Scalloping		Patchy
	Pathological vascular pattern		Generalised
	Ulcerated mucosa		V
	Pseudomembranes		V
	Melanosis		V
Flat lesions	Angioectasia	Number	Single
			Multiple
		Bleeding	Yes
			No
	Dieulafoy lesion	Number	Single
			Multiple
		Bleeding	Spurting
			Oozing
			Clot
			No
	Ectopic gastric mucosa	Size	xx mm (max)
	Flat/elevated superficial lesion	Number	Single
			Multiple
		Size	xx mm (max)
		Free margins	To relevant structure(s)
		Type	Japan classification
		Surface	Kudo classification
		Bleeding	Yes
			Stigmata
			No
Protruding lesions	Nodule	Number	Single
			Multiple

	Polyp	Number	Single
			Multiple
		Size	xx mm (max)
		Shape	Pedunculated
			Semipedunculated
			Sessile
			Flat elevated
		Surface	Kudo classification
		Appearance	Malignant
			Adenomatous
			Hyperplastic
			Inflammatory
			Pseudopolyp
		Bleeding	Yes
			Stigmata
			No
	Tumor/mass	Number	Single
			Multiple
		Size	xx mm (max)
		Free margins	To relevant structure(s)
		Type	Paris type 0-4
			Japan class for type 0
		Surface	Kudo classification
		Bleeding	Yes
			Stigmata
			No
	Varices	Number	#
		Grade	1-3
		Bleeding	Spurting
			Oozing
			Stigmata
			No
		Red signs	yes
			no
	Enlarged folds	Distribution	Localized
			Generalized
	Ectopic pancreas		
	Enlarged Brunners glands		
	Hemorrhoids	Number	#
		Grade (Goligher)	1-4
	Condylomas	Number	A few
			Multiple
Excavated lesions	Erosion	Number	Single
			Multiple
		Bleeding	Yes
			Stigmata
			No

	Depressed superficial lesion	Number	Single
			Multiple
		Size	mm (max)
		Free margins	To relevant structure(s)
		Type	Japan classification
		Surface	Kudo classification
		Bleeding	Yes
			Stigmata
			No
	Ulcer	Number	
		Size	xx mm (max)
		Depth	Superficial
			Cratered
		Shape	Round
			Linear
			Irregular
		Bleeding	Forrest classification
	Scar		
	Fistula	Communicating organ	specify
	Perforation	type	Mediastinal
			Free peritoneal
			Retroperitoneal
	Mallory-Weiss tear	Bleeding	Spurting
			Oozing
			Stigmata
			No
	Anal fissure		

3.2 Luminal findings per organ

This table indicates what terms would be relevant within the categories for each of the organs. It shows very clearly that most of the terms are indeed valid for most of the organs.

		Esoph	Stomach	Duod	Jej	Ileum	Colon
Lumen	Dilation	x	x	x	x	x	x
	Stenosis	x	x	x	x	x	x
	Extrinsic compression	x	x	x	x	x	x
	Diverticulum	x	x	x	x	x	x
	Previous surgery	x	x	x	x	x	x
	Deformity		x	x			
	Ring/web	x					
	Hiatal hernia	x	x				
Z-line	x						
Contents	Foreign body	x	x	x	x	x	x
	Blood	x	x	x	x	x	x
	Food	x	x	x	x	x	

	Bezoar	x	x				
	Fluid	x	x	x	x	x	x
	Parasites	x	x	x	x	x	x
	Stent	x	x	x	x	x	x
	Rubber band	x	x				
	Metal Clip	x	x	x	x	x	x
	Gastrostomy		x				
	Faeces						x
	Exudate	x	x	x	x	x	x
Mucosa	Erythematous	x	x	x	x	x	x
	Edematous	x	x	x	x	x	x
	Granular		x	x	x	x	x
	Nodular	x	x	x	x	x	x
	Friable		x	x	x	x	x
	Hemorrhagic	x	x	x	x	x	x
	(Petechial)	x	x	x	x	x	x
	Atrophic		x	x	x	x	x
	Scarring	x	x	x	x	x	x
	Barretts esophagus	x					
	Esophagitis	x					
	Candidosis	x					
	Scalloping			x	x		
	Path. vascular pattern	x	x	x	x	x	x
	Ulcerated mucosa	x	x	x	x	x	x
	Pseudomembranes						x
	Melanosis						x
Flat lesions	Angioectasia		x	x	x	x	x
	Ectopic gastric mucosa	x					
	Dieulafoy lesion		x	x	x	x	x
	Flat/elevated superficial lesion	x	x	x	x	x	x
Protruding lesions	Nodule	x	x	x	x	x	x
	Polyp	x	x	x	x	x	x
	Tumor/mass	x	x	x	x	x	x
	Varices	x	x	x	x	x	x
	Enlarged folds		x				
	Ectopic pancreas		x	x			
	Enlarged Brunners glands			x			
	Hemorrhoids						x
Excavated lesions	Erosion	x	x	x	x	x	x
	Depressed superficial lesion	x	x	x	x	x	x
	Ulcer	x	x	x	x	x	x
	Scar	x	x	x	x	x	x
	Fistula	x	x	x	x	x	x

Perforation	x	x	x	X	X	x
Mallory-Weiss tear	x					
Anal fissure						x

3.3 ERCP findings

Due to the differences between luminal anatomy of the GI tract and the findings in the hepatobiliary region, these findings have been set up separately. However, the principles are the same.

Heading	Term	Attribute	Attr values
Papillary features		Location	Normal
			High position
			Low position
			3rd part of duodenum
			Intradiverticular
			On edge of diverticulum
		Appearance	Normal
			Hidden
			Small
			Adenomatous
			Infiltrated
			Congested
			Lacerated
			Previous EPT
			Previous fistulotomy
			Previous sphincteroplasty
			Previous ampullectomy
		Output	None
			Bile
		Pus	
		Debris	
		Blood	
		Mucin	
		Parasites	
Ductal variants	Pancreas divisum	type	Complete
			Incomplete
	Pancreas annulare		
	Common channel	Length	mm
	Cystic duct implant	location	high
			low
	hepatic duct anomaly	type	specify
Ductal pathology	Irregularity	Distribution	Localized
			Generalized
	Dilation	Type	Localized-cystic

			Generalized-prestenotic
	Stenosis	Length	in mm
		Degree	Moderate
			Passable by catheter
			Passable by wire
			Not passable
		Type	Extrinsic
			Intrinsic
	Stone	Number	Single
			Multiple
		Size	mm (biggest)
		Obstructing	Yes
			No
	Tumor	Type	Localized
			Diffuse
		Obstructing	yes
			partially
			no
		Bismuth classification	Type I-IV
	Cavity	Number	Single
			Multiple
		Size	in mm
	Fistula	communicating structure	specify
	Leak	Degree	Small
			Moderate
			Large
	Extravasation		
	Parenchymal filling		
	Stent	Type	specify
		Number	Specify
		Migrated	Inward
			Outward
	Filling defects	Type	sludge
			air bubbles
			parasites
			stent/t-tube
			mucus
			Protein plugs
			casts
	Previous surgery	Type	specify

3.4 ERCP findings per organ

		Maj pap	Min pap	Bile tree	Panc duct
Location	Normal	X	X		
	High position	x	x		
	Low position	x	x		
	3rd part of duodenum	x	x		
	Inside diverticulum	x	x		

	At edge of diverticulum	x	x		
Output	None	x	x		
	Bile	x	x		
	Pus	x	x		
	Debris	x	x		
	Blood	x	X		
	Mucin	x	X		
	Parasites	x			
Appearance	Normal	x	x		
	Hidden	x	x		
	Small	x	x		
	Adenomatous	x	x		
	Infiltrated	x	x		
	Congested	x	x		
	Lacerated	x	x		
	Previous EPT	x	x		
	Previous fistulotomy	x			
	Prev.sphincteroplasty	x			
	Prev.ampulectomy	x			
Ductal anomaly	Pancreas divisum				x
	Pancreas annulare				x
	Cystic duct implant			x	
	Hepatic duct implant			x	
Ductal pathology	Irregularity			x	x
	Dilation			x	x
	Stenosis			x	x
	Stone			x	x
	Tumor			x	x
	Cavity			x	x
	Fistula			x	x
	Leak			x	x
	Extravasation			x	x
	Parenchymal filling			x	x
	Stent			x	x
	Filling defects			x	x
	Previous surgery			x	x

3.5 EUS findings

(table in 3 parts)

	Location	Origin	Layer origin	Outer limit	Size
Intramural lesion	x		x	x	x
Wall thickening	x		x		x

Polyp	x		x		x
Mass	x	x	x	x	x
Lymph node(s)	x				x
Stricture	x				
Extramural mass	x	x			x
Varices	x				x
Collaterals	x				
Pleural effusion	x				
Cardiac effusion					
Ascites					
Cyst	x				x
Parenchymal changes	x				
Pancreatic duct changes	x				
Calcification	x				x
Ventral anlage					
Pancreatic stent	x				
Bile duct changes	x				
Cholelithiasis	x				x
Gallbladder sludge					
Biliary stent	x				
Pancreas divisum					
FINDING ATTRIBUTES		Origin	Layer origin	Outer limit	
		relevant organs	mucosa	mucosa	
			muscularis mucosa	m. Mucosa	
			submucosa	submucosa	
			muscularis propria	m propria beyond m. propria	
				Transmural	
				All layers	
				Indeterminate	

	shape/character	Margins	Echofeatures	Cyst features
Intramural lesion	x	x	x	
Wall thickening			x	
Polyp	x	x	x	
Mass	x	x	x	
Lymph node(s)	x	x	x	
Stricture				
Extramural mass	x	x	x	
Varices	x			
Collaterals	x			
Pleural effusion				
Cardiac effusion				
Ascites				
Cyst	x	x		x
Parenchymal changes	x		x	

	shape/character	Margins	Echofeatures	Cyst features
Pancreatic duct changes	x			
Calcification	x			
Ventral anlage				
Pancreatic stent				
Bile duct changes				
Cholelithiasis			x	
Gallbladder sludge				
Biliary stent				
Pancreas divisum				
	round	well defined	normal	anechoic
	oval	poorly defined	anechoic	homogeneous
	triangular	smooth	hypoechoic	heterogeneous
	crescent-shaped	irregular	isoechoic	debris present
	tortuous	encasing	hyperechoic	septated
	tubular	abutting	hyperechoic foci	unilocular
	lobulated	loss of interface	hyperechoic strands	multilocular
	sessile	invading	granular	microcystic
	pedunculated	intraluminal growth	homogeneous	macrocystic
	ulcerated		heterogeneous	no of cysts
	irregular		cystic components	microcyst size
	circumferential		solid	wall thickness
	enlarged		shadowing	wall irregularity
	atrophic		distal enhancement	mural nodules
	diffuse			calcification
	generalized			duct communication
	localized			associated mass
	size/number:...			

	Invasion ext	invasion into	T-stage	N-stage	degree	number	duct changes
Intramural lesion	x	x					
Wall thickening							
Polyp							
Mass	x	x	x	x			
Lymph node(s)						x	
Stricture			x	x	x		
Extramural mass	x	x	x	x			
Varices					x		
Collaterals					x		
Pleural effusion					x		
Cardiac effusion					x		
Ascites					x		
Cyst							
Parenchymal changes					x		
Pancr. duct changes					x		x
Calcification							

Extramural mass		x							x
Varices									
Collaterals							x	x	x
Cyst		x							x
Parenchymal changes						x	x	x	
Pancr. duct changes							x	x	
Calcification							x	x	

3.6.2 Echofeatures

Echofeatures	normal	anechoic	hypoechoic	isoechoic	hyperechoic	hyperechoic foci	hyperechoic strands	granular
Intramural lesion		x	x	x	x			
Wall thickening		x	x	x	x			
Polyp		x	x	x	x			
Mass			x	x	x			
Lymph node(s)			x	x	x	x		
Extramural mass	x							
Parenchymal changes			x	x	x	x	x	x
Cholelithiasis					x			

...cont.

Echofeatures	homogeneous	heterogeneous	cystic components	solid	shadowing	distal enhancement
Intramural lesion	x	x	x	x	x	x
Wall thickening	x	x	x	x	x	x
Polyp	x	x	x	x	x	x
Mass	x	x	x	x	x	x
Lymph node(s)	x	x	x	x	x	x
Extramural mass						
Parenchymal changes	x	x	x	x		
Cholelithiasis	x	x			x	

3.7 EUS findings per organ

	Esophagus	Stomach	Duodenum	Pancreas	Biliary tree	Colorectal
Intramural lesion	x	x	x		x	x
Wall thickening	x	x	x		x	x
Polyp	x	x	x			x
Mass	x	x	x	x	x	x
Lymph node(s)	x	x	x	x	x	x
Stricture	x		x		x	x
Extramural mass	x	x	x		x	x
Cyst	x	x	x	x	x	x
Varices	x	x				
Collaterals	x	x				x
Pleural effusion	x					
Cardiac effusion	x					

Ascites		x		x			x
Perianal fistula							x
Parenchymal changes					x		
Pancreatic duct changes					x		
Calcification					x		
Ventral anlage					x		
Pancreatic stent					x		
Bile duct changes						x	
Cholelithiasis						x	
Choledochocele						x	
Gallbladder sludge						x	
Biliary stent						x	
Other	x	x	x	x	x	x	x

4 Reasons for endoscopy

Indications are often used in place of reasons for endoscopy. An indication is often used to define the reason for an endoscopy which complies with generally accepted standards of practice. There may be reasons for an endoscopy which are not indications. For example, a patient may want to undergo annual colonoscopy for colorectal cancer surveillance even though there is no prior history of polyps or family history of colon cancer.

"Reasons for " have been divided into *symptoms* and *diseases*. . For the symptoms, a qualifier for *duration* and/or *degree* may be relevant. For diseases, the following qualifiers may all be relevant: *Suspected, established, follow-up of..., sampling of..., treatment of... and screening for....* Screening will cover normal risk, as well as high risk individuals without previous findings.

If a disease is implicated, a disease should be listed as the indication. If the software allows several reasons/indications, then diseases should be prioritized to symptoms.

4.1 Upper endoscopy

Category	Term	Qualifier
Symptoms	Abdominal distress/pain	Duration
	Dyspepsia	Degree
	Heartburn	
	Dysphagia	
	Odynophagia	
	Vomiting	
	Hematemesis	
	Melena	
	Nausea	
	Weight loss	
	Anemia	
	Diarrhea	
Diseases	Achalasia	Suspected
	Anastomic leak	Established
	Angioectasia	Follow-up of
	Atrophic gastritis	Sampling of
	Barretts esophagus	Treatment of
	Caustic ingestion	Screening for
	Celiac disease	
	Diverticulum	
	Duodenal stricture	
	Duodenal ulcer	
	Esophageal stricture	
	Esophageal varices	
	Fistula	
	Foreign body	
	Gastric ulcer	
	Gastric varices	
	GERD	
	Lymphoma	
Metastasis, unknown origin		

	Other esophagitis	
	Pernicious anaemia	
	Polyp	
	Precancerous lesions	
	Pyloric stenosis	
	Reflux esophagitis	
	Superficial neoplastic lesion	
	Tumor/mass	

4.2 Colonoscopy

Category	Term	Qualifier
Symptoms	Hematochezia	Duration
	Melena	Degree
	Diarrhea	
	Abdominal distress/pain	
	Altered bowel habits	
	Anemia	
	Weight loss	
	Constipation	
	Defecation disorder	
	Abdominal mass	
Diseases	Anastomotic leak	Suspected
	Angioectasia	Established
	Colonic obstruction	Follow-up of
	Colorectal cancer	Sampling of
	Crohns disease	Treatment of
	Diverticula	Screening for
	Endocrine mass	
	Fistula	
	Ischemic colitis	
	Metastasis, unknown origin	
	Other colitis	
	Polyps	
	Pouchitis	
	Pseudomembranous colitis	
	Superficial neoplastic lesion	
Ulcerative colitis		

4.3 Enteroscopy

Category	Term	Qualifier
Symptoms	Abdominal distress/pain	Duration

	Vomiting	Degree
	Melena	
	Anemia	
	Diarrhea	
Diseases	Angioectasia	Suspected
	Celiac disease	Established
	Crohns disease	Follow-up of
	Hereditary polyposis syndrome	Sampling of
	Lymphoma	Treatment of
	NSAID enteropathy	Screening for
	Polyps	
	Stricture	
	mass	

4.4 ERCP

Category	Term	Qualifier
Symptoms	Jaundice	Duration
	Pancreatobiliary pain	Degree
	Pruritus	
Diseases	Acute pancreatitis	Suspected
	Ampullary mass	Established
	Anastomotic stricture	Follow-up of
	Bile duct injury	Sampling of
	Bile duct leak	Treatment of
	Bile duct stone	Screening for
	Bile duct stricture	
	Carolis disease	
	Choledochal cyst	
	Choledochocele	
	Chronic pancreatitis	
	Fistula	
	Gallbladder polyp	
	Gallbladder stone	
	Gallbladder mass	
	Hepatobiliary mass	
	IPMT	
	Mirizzi syndrome	
	Pancreatic duct leak	
	Pancreatic injury	
	Pancreatic pseudocyst	
	Pancreatic stone	
	Pancreatic mass	
	Papillary dysfunction	
	Parasites	
	Parenchymal liver disease	

	Primary sclerosing cholangitis	
	Purulent cholangitis	
	Stent dysfunction	

4.5 EUS

Category	Term	Qualifier
Symptoms	Abdominal pain	Duration
	Diarrhea	Degree
	Jaundice	
	Pancreatobiliary pain	
	Weight loss	
Diseases	Abdominal mass	Suspected
	Ampullary mass	Established
	Bile duct mass	Follow-up of
	Bile duct stone	Sampling of
	Bile duct stricture	Staging of
	Colorectal intramural lesion	Treatment of
	Colorectal mass	Screening for
	Colorectal stricture	
	Duodenal intramural lesion	
	Duodenal mass	
	Duodenal stricture	
	Esophageal intramural lesion	
	Esophageal mass	
	Esophageal stricture	
	Gastric intramural lesion	
	Gastric mass	
	Liver mass	
	Mediastinal lymph node/mass	
	Pancreatic cyst	
	Pancreatic mass	
	Pancreatic pseudocyst	
	Pancreatic stone	
	Pancreatitis - acute	
	Pancreatitis - chronic	
Perirectal mass		
Pulmonary mass		

5 Endoscopic diagnosis

5.1 Upper endoscopy

Term
Aberrant pancreas
Achalasia
Barretts esophagus
Benign stricture
Bleeding of unknown origin
Coeliac disease
Crohns disease
Dieulafoy lesion
Duodenal benign tumor
Duodenal bulb deformity
Duodenal cancer
Duodenal diverticulum
Duodenal fistula
Duodenal polyp
Duodenal postoperative appearance
Duodenal submucosal tumor
Duodenal superficial neoplasm
Duodenal ulcer
Duodenal ulcer with bleeding
Duodenopathy - erosive
Duodenopathy - hemorrhagic
Duodenopathy - hyperemic
Eosinophilic esophagitis
Esophageal benign tumor
Esophageal caustic injury
Esophageal cancer
Esophageal candidiasis
Esophageal diverticulum
Esophageal fistula
Esophageal foreign body
Esophageal polyp
Esophageal postoperative appearance
Esophageal stricture
Esophageal superficial neoplasm
Esophageal submucosal tumor
Esophageal varices
Extrinsic compression
Gastric benign tumor
Gastric cancer
Gastric diverticulum
Gastric fistula
Gastric foreign body

Gastric caustic injury
Gastric lymphoma
Gastric polyp(s)
Gastric postoperative appearance
Gastric retention
Gastric submucosal tumor
Gastric superficial neoplasm
Gastric ulcer
Gastric ulcer with bleeding
Gastric ulcer-anastomotic
Gastric varices
Gastropathy-erosive
Gastropathy-hemorrhagic
Gastropathy-hyperemic
Gastropathy-hypertrophic
Gastropathy-NSAID-related
Gastropathy-portal hypertensive
Gastropathy-varioloform
Hiatus hernia
Mallory-Weiss tear
Other esophagitis
Parasites
Post sclerotherapy appearance
Pyloric stenosis
Reflux esophagitis
Schatzki ring
Scar
Submucosal tumor

5.2 Colonoscopy

Term
Angiodysplasia
Bleeding of unknown origin
Colitis - ischemic
Colitis - pseudomembranous
Colorectal cancer
Colorectal superficial neoplasm
Condylomata
Crohns disease - active
Crohns disease - fulminant
Crohns disease - quiescent
Diverticulitis
Diverticulosis
Fistula
Foreign body
Hemorrhoids
Ileitis

Lipoma
Lymphoma
Melanosis
Parasites
Pneumatosis coli
Polyp
Polyposis syndrome
Postoperative appearance
Proctitis
Rectal ulcer
Solitary ulcer
Stricture - inflammatory
Stricture - malignant
Stricture - postoperative
Submucosal tumor
Ulcerative colitis - active
Ulcerative colitis - fulminant
Ulcerative colitis – quiescent

5.3 Enteroscopy

Term
Angioectasia
Bleeding, unknown origin
Celiac disease
Crohns disease
Diverticula
Enteropathy - erosive
Enteropathy - hemorrhagic
Enteropathy - hyperemic
Enteropathy - NSAID-related
Erosions
FAP
GIST
Graft v host disease
Juvenile polyposis
Lipoma
Lymphangioectasia
Lymphoma
NSAID-enteropathy
Parasites
Peutz-Jæger polyposis
Polyp(s)
Radiation enteritis
Small bowel benign tumor
Small bowel malignant tumor
Small bowel superficial neoplasm
Submucosal tumor
Ulcer

5.4 ERCP⁴

Term
Abnormal pancreatobiliary junction
Anastomotic stricture
Biliary fistula/leak
Biliary injury
Biliary occlusion
Biliary stent occlusion
Biliary stone(s)
Biliary stricture
Carolis disease
Choledochal cyst
Choledochocele
Cystic duct stones
Gallbladder stone(s)
Gallbladder tumor
Hemobilia
IPMT
Kolangiocarcinoma
Liver parenchymal disease
Mirizzi syndrome
Pancreas annulare
Pancreas divisum
Pancreatic cyst
Pancreatic duct fistula/leak
Pancreatic duct injury
Pancreatic duct stricture
Pancreatic stent occlusion
Pancreatic stone
Pancreatic tumor
Pancreatitis - acute
Pancreatitis - chronic
Papillary stenosis
Papillary tumor
Primary sclerosing cholangitis
Sump syndrome
Suppurative cholangitis

5.5 EUS

Term

⁴ Upper endoscopy diagnoses may be relevant for the luminal part of the ERCP procedure as well

Aortic aneurysm
Ascites
Bile duct dilation
Bile duct stone
Bile duct stricture
Bile duct tumor
Biliary sludge
Colorectal cancer
Colorectal polyp
Colorectal stricture
Colorectal submucosal mass
Colorectal ulcer
Crohns disease
Duodenal cancer
Duodenal polyp
Duodenal stricture
Duodenal submucosal mass
Duodenal ulcer
Endocrine tumor
Esophageal cancer
Esophageal mass
Esophageal polyp
Esophageal stricture
Esophageal submucosal mass
Esophageal ulcer
Gallbladder sludge
Gallbladder stone
Gastric cancer
Gastric polyp
Gastric submucosal mass
Gastric ulcer
GIST tumor
IPMT
linitis plastica
lipoma
lymphoma
Mediastinal lymph node(s)
Mediastinal mass
Menetrier's disease
Mesenteric artery aneurysm
Pancreas divisum
Pancreatic cancer
Pancreatic duct dilation
Pancreatic duct stricture
Pancreatic mass
Pancreatic pseudocyst
Pancreatic stone
Pancreatitis - acute
Pancreatitis - chronic
Papillary mass

Pericardial effusion
Pleural effusion
Polyp
portal vein thrombosis
postradiation changes
pseudoaneurysm
Splenic artery aneurysm
Submucosal tumor
TNM-stage
Ulcerative colitis
Varices
Wall thickening

6 Procedures

Procedures should be described, both in terms of technical aspects and whether the aim of the procedure was achieved.

Because some procedures are difficult to connect directly to a described finding, procedures are suggested to be linked generally to the endoscopy per se, not to lesions. However, software should be able to connect the two as needed. Thus, sampling, as well as treatment of a lesion should be available linked to the description of the lesion itself. The choice of treatment modalities should be adapted to the individual lesions, to avoid listing of irrelevant procedures.

6.1 Luminal procedures

Method	Attribute	Attribute values	
Sampling	Lesion	Link to relevant finding OR	
		Normal location(s)	
	type	Biopsy	
		incomplete removal	
		complete piecemeal removal	
		en-bloc removal	
		brush sampling	
		fluid sampling	
		Final reading	<i>Late entry</i>
	Balloon dilation	(type) ⁵	Specify
Caliber		Specify	
Time		Specify	
End caliber		Specify	
Bougie dilation	Start caliber	Specify	
	End caliber	Specify	
Band ligation	Number	Specify	
	Result	Success	
		Partial success	
		Failure	
Injection therapy	Material	Specify	
	Volume	Specify	
	Result	Success	

⁵ Type/tool details should be optional for most procedures.

		Partial success
		Failure
Clipping	(Type)	Specify
	Number	Specify
	Result	Success
		Partial success
		Failure
Cautery	(Type)	Specify
	Result	Success
		Partial success
		Failure
APC	Gas used	ml
	Result	Success
		Partial success
		Failure
Polypectomy	Method	Snare only
		Loop and snare
		Clips and snare
	Pre-injection	yes/no
	Pre-inj fluid	Pre-inj fluid
	Pre-inj volume	ml
	Result	Success
		Partial success
		Failure
Hot biopsy	Result	Success
		Partial success
		Failure
Foreign body removal	Tool	Specify
	Result	Success
		Partial success
		Failure
EMR	Tool	Specify

	Pre-inj fluid	Specify
	Pre-inj volume	ml
	Result	En bloc resection
		Complete piece-meal resection
		Partial resection
		Failure
	Specimen size	mm
ESD	Tool	Specify
	Pre-inj fluid	Specify
	Pre-inj volume	ml
	Result	En bloc resection
		Complete piece-meal resection
		Partial resection
		Failure
	Specimen size	mm
Stent placement	Type	Specify
	Size	Specify
	Pre-dilation	no/mm
	Result	Success
		Partial success
		Failure
PEG placement	Type	Specify
	Size	Specify
	Result	Success
		Failure
Tube placement	Type	Specify
	Size	Specify
	Location	Specify
	Result	Success
		Partial success
		Failure
Transmural drainage	Method	specify

	Location	Specify
	Lesion	Specify
	EUS guidance	Yes/no
	Material	specify
	Stents placed	Specify
	Result	Success
		Partial success
		Failure
Ablation therapy	Type	Specify
	Location	Specify
	Settings	Specify

6.2 ERCP procedures

Method	Attribute	Attribute values
Cannulation	Biliary	Not attempted
		Incidental
		Superficial
		Deep
		Failed
	Pancreatic	Not attempted
		Incidental
		Superficial
		Deep
		Failed
	(Minor papilla)	Not attempted
		Superficial
Deep		
Opacification	Biliary	Complete
		Incomplete, missing...
		No biliary, due to...
		No biliary intended
	Pancreatic	Complete
		Incomplete, missing...
		No pancreatic, due to..
		No pancreatic intended

Papillotomy	Type	Access/Precut
		Therapeutic
		Fistulotomy
	Tool	Wire knife
		Needle knife
	Duct	Bile duct
		Pancreatic duct
		Both ducts
Balloon dilatation	Balloon caliber	mm
	End caliber	mm
Bougie dilatation	Bougie caliber	French
	Result caliber	mm
Stone extraction	Method	Balloon
		Basket
	Fragmentation	yes
		no
	Result	Complete clearance
		Partial clearance
		Questionable
Stent placement	Type	Specify
	Number	Specify
	Size/caliber	Specify
Stent removal	Category	Transpapillary
		Upwards dislocated
	Tool	Specify
	Result	Success
		Failure
Hemostasis	Method	Injection
		Clips
		Balloon compression
		APC
		Coagulation
	Result	Success
		Partial success
		Failure

6.3 EUS procedures

Method	Attribute	Attribute values
FNA	Needle	Specify
	Passes	#
	Volume	ml or N/A
	Appearance	Specify or N/A
	Analysis	Cytology
		Bacteriology
	Chemistry	
Thru cut biopsy	Needle	Specify
	Passes	#

Celiac plexus block	Injection material	specify
	Volume	ml
	Result	Success
		Partial success
		Failure
Contrast injection	location	specify
	Result	Success
		Partial success
		Failure
Duct drainage	Method	specify
	Stents placed	Specify
	Result	Success
		Partial success
		Failure

7 Adverse events

Adverse events should be a part of the endoscopy report inasmuch they are noted at the time of the procedure. However, it must be recognized that this will not constitute a complete complications registry without post-hoc registration of late complications.

Thus, an endoscopy database should acknowledge the need for additional late data input, for complications, as well as for e.g. sampling reports.

7.1 Intraprocedure events

Type	attribute	attribute values
Perforation of lumen	Location	main sites
	Communicating to	Retroperitoneum
		Peritoneum
		Mediastinum
	type	By endoscope
		Sphincterotomy-related
		Polypectomy-related
		Dilation-related
Bleeding	location	main sites
Cardiopulmonary	type	apnoea/hypopnea
		bronchospasm
		laryngospasm
		hypotension
		hypertension
		arrest
		dysrhythmia
		aspiration
	Action	ventilation assist
		Emergency code
		<i>list below</i>
Equipment malfunction	type	specify
Equipment impaction	type	specify
Allergic reaction	agent	specify
	type	specify
	Action	ventilation assist
		Emergency code
		<i>list below</i>
Other events	Type	specify

7.2 Postprocedure events

Type	attribute	attribute values
cardiopulmonary event	type	specify
	date of onset	specify
	relation	probable

		possible
		unlikely
Abdominal pain	date of onset	specify
	relation	probable
		possible
		unlikely
Infection	type	specify
	date of onset	specify
	relation	probable
		possible
		unlikely
Thromboembolic event	type	specify
	date of onset	specify
	relation	probable
		possible
		unlikely
Late perforation	type	specify
	date of onset	specify
Late bleeding	type	specify
	date of onset	specify
Pancreatitis	date of onset	specify

7.3 Actions and outcomes

actions	<i>endoscopic intervention</i>
	<i>aborted procedure</i>
	medical intervention
	admission to hospital (days)
	admission to ICU
	repeat endoscopy
	radiologic intervention
	surgery
outcomes	recovery
	permanent disability
	died (days after procedure)

8 Appendices

8.1 Classifications

8.1.1 LA classification of erosive esophagitis

- Grade A Mucosal break < 5 mm in length
- Grade B Mucosal break > 5mm
- Grade C Mucosal break continuous between > 2 mucosal folds
- Grade D Mucosal break >75% of esophageal circumference

Reference: Lundell L, Dent J, Bennett J, et al. Endoscopic assessment of esophagitis: clinical and functional correlates and further validation of Los Angeles classification. *Gut* 1999; 45:172-80

8.1.2 Size classification of esophageal varices

- grade 1 = small and nontortuous esophageal varices, flattened with insufflation
- grade 2 = tortuous esophageal varices but covering less than 50 % of the radius of the distal esophagus
- grade 3 = large and tortuous esophageal varices covering more than 50 % of the radius of the distal esophagus

Reference: Pungpapong S, Keaveny A, Raimondo M, Dickson R, Woodward T, Harnois D, Wallace: Accuracy and interobserver agreement of small-caliber vs. conventional esophagogastroduodenoscopy for evaluating esophageal varices. *Endoscopy* 2007; 39; 673-80

8.1.3 Prague C & M classification of Barretts esophagus extension

The C (Circumferential) and M (maximal) measurements are calculated, respectively, as:

- C = The difference in endoscope insertion distances between the positions recorded for the "GEJ" and the "proximal margin of the circumferential Barretts epithelium.
- M = The difference in endoscope insertion distances between the positions recorded for the "GEJ" and the "proximal margin for the longest " tongue-like" segment of Barretts epithelium (do not include Barretts islands in this assessment).

Reference: Sharma P, Dent J, Armstrong D, Bergman JJ, Gossner L, Hoshihara Y, Jankowski JA, Junghard O, Lundell L, Tytgat GN, Vieth M. The development and validation of an endoscopic grading system for Barrett's esophagus: the Prague C & M criteria. *Gastroenterology*. 2006 ;131:1392-9

8.1.4 Paris classification of neoplastic lesions

- type 0 - superficial polypoid, flat/depressed, or excavated tumors
- type 1 - polypoid carcinomas, usually attached on a wide base
- type 2 - ulcerated carcinomas with sharply demarcated and raised margins
- type 3 - ulcerated, infiltrating carcinomas without definite limits
- type 4 - nonulcerated, diffusely infiltrating carcinomas
- type 5 - unclassifiable advanced carcinomas

Reference: The Paris endoscopic classification of superficial neoplastic lesions: esophagus, stomach, and colon (no authors listed). *Gastrointestinal Endosc.*58; 6, Supplement 1: S3-S43

8.1.5 JGCA classification of superficial neoplastic lesions

- Protruding
 - pedunculated 0-1p
 - sessile 0-1s
- Non-protruding and nonexcavated
 - slightly elevated 0-IIa
 - completely flat 0-IIb
 - slightly depressed 0-Ilc
 - Elevated and depressed types 0-IIc + IIa⁶
0-IIa + IIc
- Excavated
 - Ulcer 0-III
 - Excavated and depressed types 0-IIc + III
0-III + IIc

Reference: Endoscopic classification review group. Update on the Paris endoscopic classification of superficial neoplastic lesions in the digestive tract. *Endoscopy* 2005;37:570-8

8.1.6 Forrest classification of ulcer bleeding

- Forrest I a Arterial, spurting hemorrhage
- Forrest I b Oozing hemorrhage
- Forrest II a Visible vessel g = vessel < 2mm G = vessel > 2mm
- Forrest II b Adherent clot
- Forrest II c Hematin- covered lesion
- Forrest III No signs of recent hemorrhage

Reference: Forrest JA, Finlayson ND, Shearman DJ. *Endoscopy in gastrointestinal bleeding. Lancet* 1974; 2: 394-397

8.1.7 Goligher grading of hemorrhoids

- grade 1, hemorrhoids with bleeding
- grade 2, hemorrhoids with bleeding and protrusion, with spontaneous reduction
- grade 3, hemorrhoids with bleeding and protrusion that require manual reduction
- grade 4, hemorrhoids with prolapse that cannot be replaced

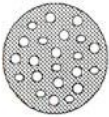






Reference: T.R. Schrock, *Hemorrhoids: nonoperative and interventional management. In: J. Barkin and C.A. O'Phelan, Editors, Advanced therapeutic endoscopy, Raven Press, New York (1991).*

8.1.8 Kudo classification of colon polyp surface pattern

In the large bowel, the organization of the surface epithelium, or pit pattern, has been analyzed with magnification and contrast and grossly classified into 5 patterns or types, which can be grouped into 3 categories: type I and type II (non

⁶ The distinction between IIa+IIc and IIc+IIa is based on the relative importance of the two features. The same applies to the distinction between IIIc+III and III+IIc.

neoplastic); type IIIS, IIIL, and IV (low-grade and high-grade intramucosal neoplasia); and type V, with distorted epithelial crests or an amorphous surface (carcinoma with suspicion of submucosal invasion).

I		Round pit (normal pit)
II		Asteroid pit
IIIS		Tubular or round pit that is smaller than the normal pit (Type I)
IIIL		Tubular or round pit that is larger than the normal pit (Type I)
IV		Dendritic or gyrus-like pit
VA		Irregular arrangement and sizes of IIIL, IIIS, IV type pit pattern
VN		Amorphous or non-structural pit pattern

Reference: Kudo S, Hirota S, Nakajima T, Hosobe S, Kusaka H, Kobayashi, et al. Colorectal tumours and pit pattern. J Clin Pathol 1994; 47:880-5.

8.1.9 Bismuth classification of cholangiocarcinoma

Type I : Extrahepatic involvement only

Type II : Extrahepatic and hilar involvement

Type IIIa: Extrahepatic, hilar and right-sided segmental involvement

Type IIIb: Extrahepatic, hilar and left-sided segmental involvement

Type IV: Extrahepatic and bilateral segmental involvement

Reference: Bismuth H, Castaing D, Traynor O. Resection or palliation: priority of surgery in the treatment of hilar cancer. World J Surg 1988; 12: 39-47

8.1.10 Definitions of the esophagogastric region

The distal esophagus and the proximal part of the stomach, or gastric **cardia**, constitute the **esophagogastric region**, with specific anatomical landmarks. There are no conspicuous proximal and distal limits of the esophagogastric region. The landmarks are selected arbitrarily: 2 cm above and below the EGJ is a frequent standard.

The EGJ (esophagogastric junction) is the point where the tubular esophagus joins the stomach at the cardia, with an angle between the opened esophagus and the gastric greater curvature. Other markers of the EGJ include the proximal extent of the gastric folds and the distal extent of longitudinal palisade vessels.

The SCJ (squamo-columnar junction, Z-line) represents the transition between esophageal squamous epithelium and the more reddish columnar epithelium. In the normal situation, this conspicuous landmark is located in the distal esophagus, just above the pinch of the diaphragm and the dilated lumen of the stomach (Diagram 1). In endoscopic vision, the normal esophagus is covered with a pale pink epithelium with an even surface; the stomach is covered with a darker epithelium with crests and pits.

In the presence of a **hiatal hernia**, the relative positions of the three endoscopic landmarks have been changed due to the intra-thoracic location of the proximal stomach. The SCJ and the anatomical junction of the esophagus with the stomach have moved to a position frankly proximal to the pinch of the diaphragm. However, the SCJ and the EGJ still coincide. The size of the hiatal hernia is measured from the EGJ to the impression of the hiatus of the diaphragm.

In the presence of **columnar metaplasia of the esophagus**, the SCJ is located proximally to the EGJ (the anatomical junction of the esophagus and stomach). With the (histological) verification of intestinal metaplasia with goblet cells, this is called **Barretts esophagus**. The extension of the metaplasia is described using the Prague C&M classification (see above).

Adapted from: Sharma P, Dent J, Armstrong D, Bergman JJ, Gossner L, Hoshihara Y, Jankowski JA, Junghard O, Lundell L, Tytgat GN, Vieth M. The development and validation of an endoscopic grading system for Barrett's esophagus: the Prague C & M criteria. Gastroenterology. 2006 131:1392-9